



# EQUINE HEALTH UPDATE

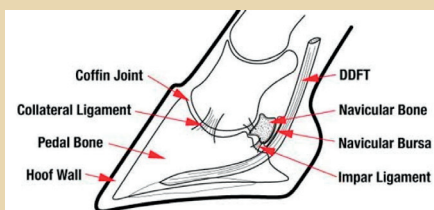
For Horse Owners and Veterinarians  
Vol. 21, Issue No. 2 – 2019

## Navicular Disease

By Brent Unruh, DVM Student (Class of 2020)  
Edited by Tim Lescun, BVSc, MS, PhD, Dipl. ACVS

### What is navicular disease?

The navicular bone is a small bone present on the backside of the foot between the short pastern bone and the coffin bone. In a healthy horse, the navicular bone functions to equally distribute mechanical forces between the coffin (pedal) bone, short pastern bone and the deep digital flexor tendon (DDFT). Therefore, navicular disease is the result of degenerative changes occurring within the navicular bone or with the soft tissue structures that make up the navicular apparatus. The navicular apparatus is comprised of the distal sesamoid impar ligament, the navicular suspensory ligament, the navicular bursa and the deep digital flexor tendon (**Figure 1**). This disease is a common cause of lameness in horses 4 to 15 years of age, encompassing roughly 30% of all lameness cases. Some will refer to navicular disease as a syndrome because the inciting cause is unknown and it typically does not affect just one structure. The source of pain is multifactorial ranging from the bone itself to components of the navicular apparatus, or a combination of both. There are two main mechanisms that are believed to result in navicular disease: vascular compromise to the foot and biomechanical abnormalities. The most accepted mechanism is that biomechanical abnormalities of the foot alter the normal forces present on the navicular apparatus leading to tissue degeneration. Alterations in the biomechanical forces can be due to poor conformation of the foot and pastern, hoof imbalances, improper shoeing or trimming, excessive weight bearing and exercise on hard surfaces.



**Figure 1.** Drawing of the normal anatomy of an equine foot.  
(<https://www.cavallo-inc.com/wp-content/uploads/elementor/thumbs/Hoof-Anatomy-ms4s03kqnax45ytdfrzshbgkmhlyiszxvaxsz8vig.jpg>)

### How do we diagnose it?

Diagnosing navicular disease can be achieved using the clinical presentation, a thorough lameness exam and imaging modalities. Horses suffering from navicular disease typically present with a progressive, bilateral forelimb lameness resulting in decreased performance, stiffness, short strides and an unwillingness to make short turns. On lameness exam, these horses may exhibit sensitivity over the frog of the foot when hoof testers are applied. Specific lameness tests and nerve blocks can be performed to further localize the origin of pain to the heel region. However, the anatomy of the equine foot is complex, so diagnosis of navicular disease must include imaging such as radiographs.

(continued on page 2)

## Contents...

### Health

Neonatal  
Isoerythrolysis. . . . .pg. 3  
Equine Recurrent  
Uveitis . . . . .pg. 6  
Navicular Disease . . . .pg. 1

### News & Notes

Research Update –  
Vitamin C and Sepsis . .pg. 5  
Who's Who? . . . . .pg. 2

### In Depth

Equine Recurrent  
Uveitis . . . . .pg. 6

Visit [vet.purdue.edu/ePubs](http://vet.purdue.edu/ePubs)  
for more information on how  
to access the newsletter through  
our PVM ePubs app.

## News & Notes



**Dr.** Jenni Auvinen is originally from a small town in Finland where she grew up spending all her free time at a local riding school. At an early age, she started grooming show jumpers, and after graduating from high school she continued to work as a groom in Finland and internationally. Ever so eager to learn more, Dr. Auvinen returned to Finland to undertake a one-

year horse massage course near home before starting her veterinary education in the United Kingdom. Dr. Auvinen graduated with honours from the University of Nottingham, School of Veterinary Medicine and Science, and moved to Canada to join the Moore Equine Veterinary Centre as an intern veterinarian. Following her internship by the Rocky Mountains, she once again followed her dream and relocated to Indiana to start her Large Animal Internal Medicine training program at Purdue University in the summer of 2019. Dr. Auvinen has a soft spot for foals and other neonates as well as naughty ponies. Her main areas of interest include neonatology, cardiovascular diseases, gastroenterology and endocrine disorders. In her spare free time, Dr. Auvinen enjoys riding horses and reading books, as well as spending time outdoors. Her plan is to explore the States with friends and family visiting from home.



**M**y name is Ahmed Khairoun. I was a senior clinician at the American Fondouk Working Equid Hospital in Fez, Morocco before I had an offer to start my Large Animal Surgery Residency at Purdue University. My ultimate goal is to become a surgeon to bring these skills back to Morocco in order to teach the next generation of Moroccan equine vets.

I am happy to know that I can use my knowledge to save equine lives, improve human livelihoods and improve equine surgery capability in my country.

I studied veterinary medicine at the IAV in Rabat, Morocco and after that I completed 4 equine internships. The first was at the American Fondouk in Fez, Morocco, the second was completed at the University of Lyon, France, the third was in private equine surgical practice at Milton Equine Hospital in Canada and my last one was at Purdue University. During my internships on these 3 different continents, I have realized that each presents different challenges and I continue to learn a wide array of procedures.

Apart from equine surgery my main passion is playing violin, especially Andalusian music. Performing for people is a truly lovely feeling.

## Navicular Disease *(continued from cover)*

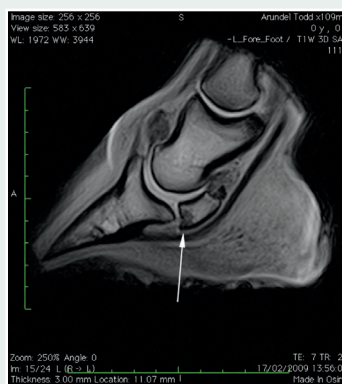Advanced imaging, which includes ultrasound, computed tomography (CT) and magnetic resonance imaging (MRI), is highly encouraged. MRI is the gold standard as it allows a more accurate assessment of bone and soft tissue structures of the foot (**Figure 2**).

### How do we treat it?

There is not a gold standard treatment for navicular disease, as it is not curable. Instead, the treatment centers around managing the level of pain present through multiple, different techniques, such as medical or surgical therapy.

### Medical Management

Medical management of navicular disease encompasses three major methods: rest and controlled exercise, corrective trimming and shoeing, and systemic and local medications. Although rest is important, it is recommended that stall rest be utilized for 3 weeks followed by 3 weeks of controlled exercise, such as walking. This period typically follows corrective shoeing allowing the horse to adjust to wearing the shoes and inflammation in the navicular apparatus to subside. The method of corrective trimming and shoeing of horses with navicular disease is crucial for the management of pain. It is imperative that the veterinarian and farrier utilize the available imaging modalities



**Figure 2.** An MRI image showing abnormalities within the navicular bone. (<https://www.yourhorse.co.uk/advice/vet-advice/articles/2016/4/19/navicular-syndrome>)

to choose the most appropriate type of shoes to restore balance to the foot and reduce biomechanical forces on the navicular apparatus. Common shoe types utilized in navicular patients include, but are not limited to, regular shoes with heel elevation and egg-bar shoes (**Figure 3 & 4**). Shoes with heel elevation decrease the tension placed on the DDFT to allow better weight distribution and reduce the pressure applied to the navicular apparatus. The main disadvantage to this shoe type is that it slows heel growth, making patient selection an important factor. Egg-bar shoes are not as effective as heel elevation shoes, but are useful in patients with underrun heels because they help redistribute weight across the sole of the foot. Systemic medications should be utilized in addition to other management techniques

*(continued on page 4)*



# Neonatal Isoerythrolysis (NI) – *Why Blood Typing Can Be Important*

By Hannah Clinton, DVM Student (Class of 2020) – Edited by Sandra D. Taylor, DVM, PhD, Dipl. ACVIM-LA

Just like a person may be “A positive” or “O negative” with respect to blood type, horses have varying blood types as well. There are many different red blood cell antigens (factors) that determine a horse’s blood type, but the Aa and the Qa antigens have the potential to cause the biggest reactions. While a horse’s blood type is important when it comes to blood transfusions, it is also important in the realm of reproduction.

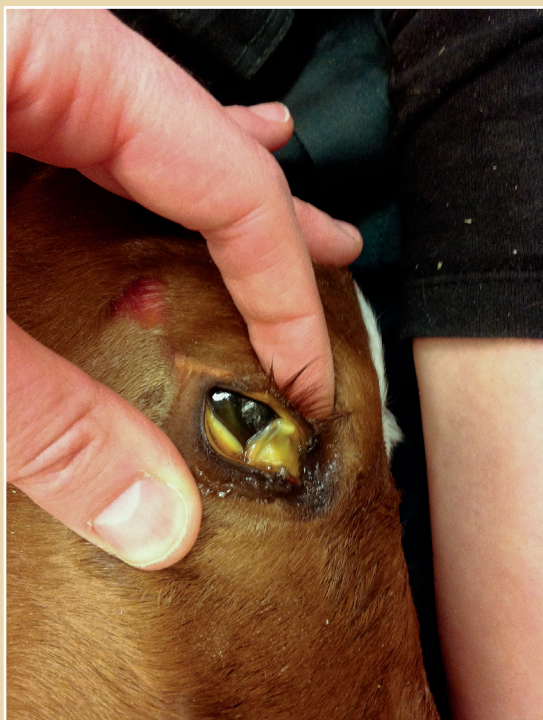If a mare does not have the Aa antigen, but the stallion does, the foal is at risk for developing a hemolytic blood disorder known as neonatal isoerythrolysis, or NI. NI is very rare and only occurs 1-2% of the time, but it is life-threatening when it happens. For NI to occur, the foal would have inherited the sire’s dominant Aa positive blood type and, during gestation, the mare will be exposed to the foal’s blood, which is recognized by the mare’s body as a foreign substance. The mare will then develop antibodies towards the foal’s blood. A second way that a mare can be exposed to a foal’s blood is during foaling, but since antibodies take time to develop, the first foal from the same mare/sire pairing is unaffected in this scenario. However, when a second foal with the same genetics is born, the mare already has anti-Aa antibodies circulating in her blood. When the foal suckles colostrum in the first 24 hours, it absorbs the

dam’s antibodies from the gut into the blood, which subsequently leads to destruction (lysis) of the foal’s red blood cells, causing hemolytic anemia.

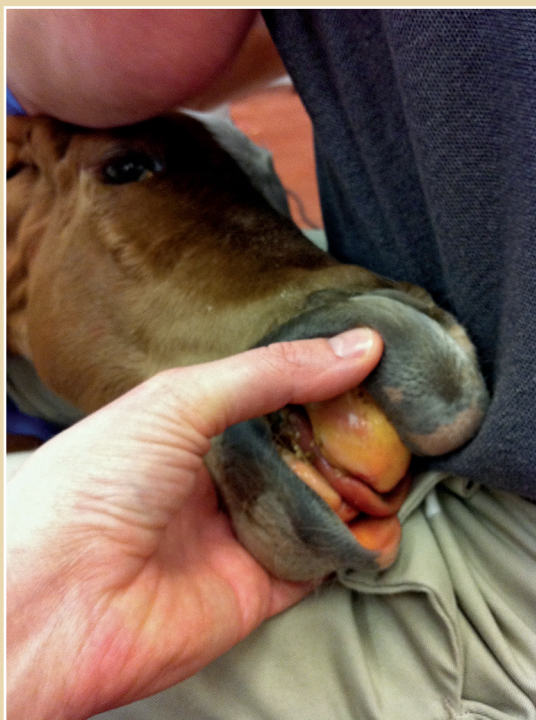A foal with NI will seem healthy at the time of foaling, but will become lethargic and depressed within the first 2-4 days of life. The foal’s mucous membranes and sclera (whites of the eyes) will appear icteric (yellow/jaundiced) due to pigment accumulation from the red blood cell destruction (**Figures 1 and 2**). How rapidly the disease progresses depends on the red blood cell antigen (Aa or Qa) and the severity of the red blood cell destruction. Seeking treatment as quickly as possible is necessary to save the foal’s life.

Most veterinarians will diagnose this disease based on the history of a multiparous mare with a foal that develops clinical signs (jaundice, weakness, depression) within a few days after birth. Bloodwork may be submitted to determine the degree of anemia and to determine if other concurrent diseases are present. If the anemia is mild, minimally handling the foal and allowing it to rest is often sufficient for recovery within a few days. However, if the PCV (red blood cell volume) is below 12% (normal: 25-30%) or if the foal is depressed and lacks a suckle reflex, a blood transfusion is appropriate.

*(continued on page 4)*



**Figure 1.** Icteric sclera and third eyelid in a foal with neonatal isoerythrolysis.



**Figure 2.** Icteric mucous membranes in a foal with neonatal isoerythrolysis.  
*(Photos courtesy of Dr. Sandy Taylor)*

## Neonatal Isoerythrolysis *(continued from page 3)*

The mare can serve as a donor if her blood is “washed” to remove antibodies, or a gelding can be used as a donor. Typically, 1-2 liters of washed red blood cells are transfused, but calculations can be performed to determine the exact amount needed for a particular foal. During treatment for NI, the foal can (and should) be allowed to nurse the mare. This is safe because after 18-24 hours, the foal’s intestines are no longer able to absorb colostral antibodies, and the colostrum (which contains these antibodies) has already been consumed.

If a mare has previously had foals that developed NI or blood typing reveals that she is at risk, assessing a potential sire’s blood type is essential for preventing this disease. If an incompatible mare and stallion are bred, the foal should be prevented from suckling at birth and provided with an alternate source of

colostrum. The foal’s antibody levels should be monitored at 18-24 hours to ensure adequate colostrum/antibody intake, and then can be allowed to return to suckling the mare thereafter.

In summary, NI is rare but life-threatening. Understanding the disease and how to prevent it can save your foal’s life. Please contact your veterinarian or the Purdue University Large Animal Medicine department if you are interested in blood typing your mare and stallion, or if you have questions. Happy foaling!

### References:


- Boyle et al. (2005). Neonatal isoerythrolysis in horse foals and a mule foal: 18 cases (1988-2003). *J Am Vet Med Assoc*, 227(8): 1276-1283.
- Munroe, G., & Weese, J. (2011). *Equine clinical medicine, surgery, and reproduction*. Manson Publishing/The Veterinary Press : CRC Press. Pages 972-974
- McCue, P. Jaundice Foal Syndrome. Colorado State University. Equine Reproduction Laboratory. <http://csu-cvmb.colostate.edu/Documents/Learnfoals8-jaundice-synd-apr09.pdf>

## Navicular Disease *(continued from page 2)*


and include non-steroidal anti-inflammatory drugs (NSAIDs) and bisphosphonates. Bisphosphonates, such as tiludronate disodium and clodronate disodium, are utilized in navicular patients with radiographic changes within the navicular bone. These drugs work to inhibit bone resorption, potentially slowing the progression of the disease. These drugs should be used carefully as they affect all bones, not just the navicular bone. Local medications are implemented by injection directly into the navicular bursa. However, injection into the bursa is difficult so injections can be placed into the coffin joint, which allows diffusion into the navicular bursa. Medications injected directly into the bursa or coffin joint decrease inflammation and support joint health. These medications include corticosteroids, polysulfated glycosaminoglycans (PSGAGs), biologics (PRP or Irap) and hyaluronic acid.

### Surgical Treatment

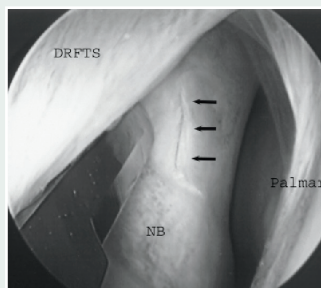
Surgical intervention for treatment of navicular disease includes navicular bursoscopy and palmar digital neurectomy. Navicular bursoscopy is a minimally invasive procedure allowing improved visualization of lesions in the navicular bursa and the DDFT (**Figure 5**). These lesions are then able to be debrided with the goal of alleviating pain from the disease. This technique can also be utilized to further diagnose the extent and presence of lesions that are not detected during other diagnostic tests. Palmar digital neurectomy is the process of the cutting the palmar digital nerve on both sides of the foot, as it is the nerve responsible for sensing pain in the foot. This is a salvage procedure and is performed when all other management modalities have failed. This procedure is contraindicated in patients with navicular disease involving the DDFT because it can increase the risk of rupturing this tendon. Other complications of this procedure include surgical site infections, nerve regrowth, and painful neuroma formation.



**Figure 3.** Regular shoe with heel elevation. (<https://i.pinimg.com/originals/bb/40/c7/bb40c775909230e148439f585cdef5ae.jpg>)



**Figure 4.** An egg-bar shoe (<https://www.willowbrookequinefarriers.co.uk/>)

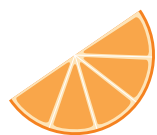

**Figure 5.** Image during a navicular bursoscopy showing a lesion on the navicular bone. (<https://www.semanticscholar.org/paper/Navicular-bursoscopy-in-the-horse%3A-a-comparative-Haupt-Caron/3836831fe54306ae4622d602a96b704e194cfd83/figure/6>)

### References:

1. Baxter, Gary M. Adams and Stashaks *Lameness in Horses*. Wiley-Blackwell a John Wiley & Sons, Ltd., Publication, 2011.
2. Smith, M. R. W., and I. M. Wright. “Endoscopic Evaluation of the Navicular Bursa: Observations, Treatment and Outcome in 92 Cases with Identified Pathology.” *Equine Veterinary Journal*, vol. 44, no. 3, 2011, pp. 339-345., doi:10.1111/j.2042-3306.2011.00443.x.
3. Frevel, M., et al. “Multi-Centre Field Trial to Evaluate the Effectiveness of Clodronic Acid for Navicular Syndrome.” *Equine Veterinary Journal*, vol. 46, 2014, pp. 5-6., doi:10.1111/evj.12323\_10.
4. Stoltz, Jennifer A. “Literature Review of Three Common Equine Hoof Ailments: Laminitis, Thrush and Navicular Disease.” *JUST*, VI, 1 Nov. 2018, pp. 1-7.
5. Dabareiner, Robin M, and G.kent Carter. “Diagnosis, Treatment, and Farriery for Horses with Chronic Heel Pain.” *Veterinary Clinics of North America: Equine Practice*, vol. 19, no. 2, 2003, pp. 417-441., doi:10.1016/s0749-0739(03)00025-7.
6. Marcella, Kenneth. Bisphosphonates and Navicular Syndrome in Horses - News Center. <http://veterinarynews.dvm360.com/bisphosphonates-and-navicular-syndrome-horses>.





## Oranges for Horses?

### Exploring Vitamin C in the Fight against Equine Sepsis

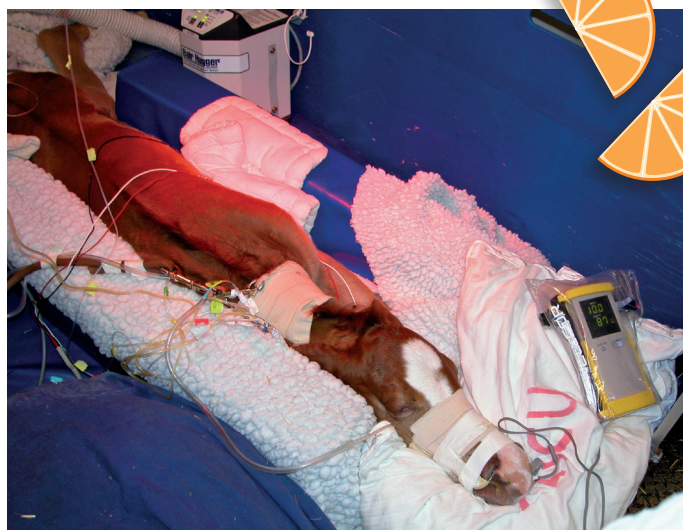By Sandra D. Taylor, DVM, PhD, Dipl. ACVIM-LA

For years, Vitamin C (ascorbic acid) has been recognized for its ability to help us fight off the common cold and shorten the time that we're out of commission! You may have taken supplements like Emergen-C® and Airborne® to boost your immune system during flu season, since Vitamin C is a powerful antioxidant and can be "used up" during illness.<sup>1</sup> Since humans cannot make their own Vitamin C, severe depletion can lead to "scurvy."

Horses are different from people in that they can make their own Vitamin C, but their Vitamin C stores can also become depleted during illness. This is especially true of severe illness, such as sepsis. Sepsis is defined as systemic ("whole-body") inflammation secondary to infection, and is common in neonatal foals that don't ingest adequate amounts of immunoglobulins in the dam's colostrum (**Figure 1**), and in adult horses with severe pneumonia or enterocolitis. Septicemia is a term that specifically refers to infection within the bloodstream. Giving appropriate antibiotics is usually sufficient for eliminating infection in septic horses, but it is currently very difficult to treat the systemic inflammation that has gone haywire and become more exuberant than necessary. This inflammation is associated with oxidative stress (excessive free radical production throughout the body) and release of inflammatory mediators that can lead to decreased oxygen delivery to tissues and subsequent organ failure. An intensive care approach to treatment typically includes antibiotics, intravenous (IV) fluid support, blood pressure support, and IV nutrition. In adult horses, keeping the feet cold is important to help prevent development of laminitis ("founder"). Even with intensive treatment, the survival rate of septic horses is only 60-70%.<sup>2,3</sup>

Vitamin C is well-known for its antioxidant effects, but its lesser-known qualities, including its anti-inflammatory and anti-bacterial properties, are just as important. Vitamin C has been shown to improve the efficiency with which white blood cells eliminate pathogens, and it also increases production of other antioxidants, including Vitamin E (*α*-tocopherol). In people, a transporter protein in the gastrointestinal tract limits the amount of Vitamin C that can be absorbed into the blood stream to approximately 500 mg per dose.<sup>4</sup> This means that if high doses are needed, Vitamin C must be given intramuscularly (IM) or IV. It is unknown whether or not there is a similar limit to intestinal absorption of Vitamin C in horses, but IM or IV administration are reasonable options.

A recent study led by Dr. Sandra Taylor and Dr. Mindy Anderson at Purdue University's College of Veterinary Medicine showed that when Vitamin C was given IV to septic horses, the white blood cells were protected from destruction by bacteria. Furthermore, the sepsis itself decreased Vitamin C levels in



**Figure 1.**  
*Neonatal foal with sepsis undergoing intensive treatment.*

the blood of most horses prior to Vitamin C administration. A separate study conducted by the same researchers in collaboration with the University of Georgia's College of Veterinary Medicine found that the higher the IV dose of Vitamin C given to healthy horses, the better the antioxidant capacity within the blood. These studies have paved the way for a future multi-center clinical trial in septic horses that present to the Purdue University Veterinary Teaching Hospital, other university veterinary teaching hospitals, and equine private practices to compare the outcome of horses treated with Vitamin C compared to those not treated with Vitamin C. We expect that Vitamin C administration will improve outcome, and that it might become an inexpensive standard-of-care treatment option for septic horses. Step-wise studies of this nature are critical for implementation of new treatment options for any disease, and researchers at Purdue University are committed to leading such studies with the end-goal of improving the health and welfare of horses worldwide.

It is likely that if Vitamin C is found to be beneficial in treating septic horses, high doses will be required and therefore will need to be given IM or IV. Alas, feeding a bunch of oranges likely won't cut it! Stay tuned for results and recommendations!

#### References:

1. Schorah CJ, Downing C, Piripitsi A, et al. Total vitamin C, ascorbic acid, and dehydroascorbic acid concentrations in plasma of critically ill patients. *Am J Clin Nutr* 1996;63:760-765.
2. Arroyo MG, Slovis NM, Moore GE, et al. Factors Associated with Survival in 97 Horses with Septic Pleuropneumonia. *J Vet Intern Med* 2017;31:894-900.
3. Armengou L, Jose-Cunilleras E, Rios J, et al. Metabolic and endocrine profiles in sick neonatal foals are related to survival. *J Vet Intern Med* 2013;27:567-575.
4. MacDonald L, Thumser AE, Sharp P. Decreased expression of the vitamin C transporter SVCT1 by ascorbic acid in a human intestinal epithelial cell line. *Br J Nutr* 2002;87:97-100.



# Moon or Immune Blindness – *An Update on Equine Recurrent Uveitis*

By Jessica White, DVM Student (Class of 2020) – Edited by Wendy Townsend, DVM, Dipl. ACVO

**E**quine recurrent uveitis (ERU), better known to some as “moon blindness,” has been documented as far back as 4<sup>th</sup> century AD when scholars suspected this fluctuant condition of the equine eye was due to changes in the moon. ERU is considered an immune-mediated disease that results in recurrence after a primary uveitis caused by infectious agents, environmental factors, and/or genetics. As the most common cause of blindness in horses, ERU is seen across many breeds and ages, but is most common in breeds such as Appaloosas, draft breeds, Knabstruppers, Icelandics, and some warmbloods. Two methods of classifying ERU exist: stage of disease and disease presentation. Stage of disease is broken into active (aka acute), quiescent, or end-stage. A horse with active ERU will have visible discomfort and inflammation of the eye as well as intra-ocular inflammation compared to a horse with quiescent ERU that will visibly appear comfortable with no evidence of current intraocular inflammation. End stage ERU is characterized by changes from chronic inflammation such as phthisis bulbi (a shrunken, nonfunctional eye) and vision loss, with or without cataracts, lens luxation, retinal detachment, or abnormal pupil structure. The three presentations of ERU are classic recurrent, insidious, and primary posterior. Classic ERU consists of an active episode, followed by periods of quiescent then recurrent active ERU. The insidious ERU horse will appear comfortable in the affected eye but has persistent low-level inflammation in the affected eye and is most common in Appaloosas, Knabstruppers, and draft breeds. Posterior ERU is less common than the other two but originates from inflammation of structures in the back of the eye rather than the front.

Several key signs that should make you suspicious of ocular disease are squinting, tearing, miosis (a small constricted pupil), redness or swelling of the tissues around the eye, and changes in the color, opacity, and surface of the cornea. Call your vet immediately if you have eye concerns as these can progress very quickly and may need immediate intervention.

Upon examination, your veterinarian will conduct a physical and complete ophthalmologic exam to assess what changes they see in the eye, determine what the potential causes are, and what further diagnostic tests and treatments they would like to recommend. Further diagnostics will often include a fluorescein stain of the cornea to check for ulcers, applying a topical anesthetic to the cornea to facilitate examination of the area around the eye, and tonometry to measure intraocular pressure. Depending on your region and index of suspicion by

your veterinarian, Leptospirosis testing may be indicated for the bacteria *L. pomona* which is a documented cause of ERU in some cases. If Leptospirosis is strongly suspected as the cause of active uveitis, the systemic antibiotic doxycycline will also be included in the treatment plan.

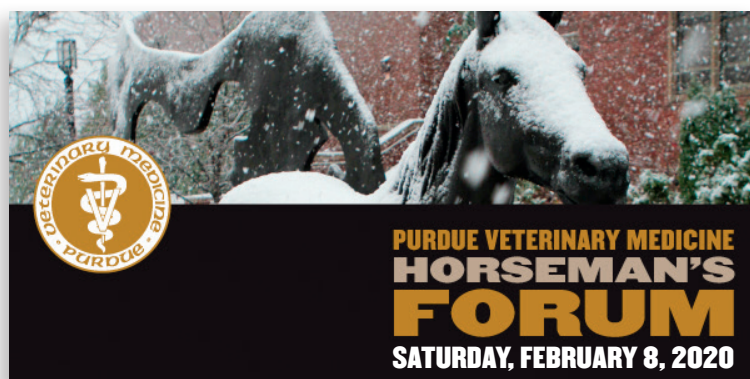Once your veterinarian rules out other conditions, long-term treatment will be required to preserve vision and keep your horse comfortable. However, the prognosis for vision long-term is poor. The mainstays of medical treatment for ERU include mydriatics (pupillary dilators) and anti-inflammatories. Mydriatics, like atropine, are topically applied 1-3 times/daily to treat ocular spasms and pain from intraocular inflammation. Anti-inflammatories consist of topical and systemic steroids and/NSAIDs to help decrease inflammation, control pain, and preserve vision.

Intravitreal injections of gentamicin (IVG) have been evaluated and deemed effective in treating ERU that is refractory to core treatments. In IVG, the antibiotic gentamicin is injected into the gelatinous tissue in the eye called the vitreous and has been shown to have low complication rates and <15% recurrence rates.

Current surgical treatment options consist of cyclosporine implants or a procedure called a pars plana vitrectomy (PPV). Cyclosporine implants are sustained-release devices discharging consistent levels of this immunosuppressive drug to provide long-term control of inflammation and very low recurrence rates. The best candidates for cyclosporine implants are horses with well-controlled ERU but are looking for a more long-term treatment option than the current mainstay topical and systemic medications. In PPV the vitreous is removed while the horse is under general anesthesia. Candidates for PPV are ERU cases with recurrent posterior segment inflammation but whose disease is well-controlled on medications so as not to have difficulty post-operatively.

Stable management is key to reducing recurrence of these episodes of inflammation as well as good, consistent health maintenance. Environmental considerations to decrease ERU include improving rodent control to decrease leptospira exposure. Minimizing eye trauma is also crucial by giving horses a good quality fly mask, removing pasture weeds or low branches, avoiding using hay nets, and softening objects in their environment, i.e. tape over bucket handles. Proper maintenance of the ERU horse includes keeping up with good hoof and dental care, as well as optimized nutrition and deworming plans. Additionally, in horses with ERU it is best to

*(continued on page 7)*



## Registration Open for Purdue Horseman's Forum

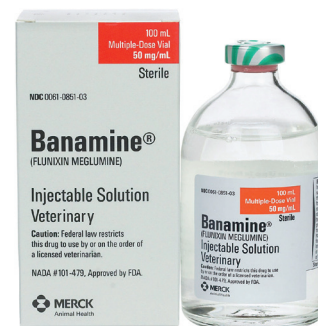The 2020 Horseman's Forum will take place on Saturday, February 8, 2020, in Lynn Hall on the Purdue University West Lafayette campus. This one-day program is designed to educate horse owners and equine industry professionals about current horse health issues, ranging from basic preventive health care and husbandry topics to state-of-the-art medical advancements. 2020 Horseman's Forum topics include: tendon and ligament injuries, headshaking, equine asthma, colic, and trailering. Afternoon demonstrations during the program are: dental health, bandaging, lameness locator, and treadmill with endoscopy. Registration is now open! Group discounts are available for groups of 5 or more registering together. For more information, go to <https://www.purdue.edu/vet/ce/horsemans.php> or contact Andrea Brown at [ahbrown@purdue.edu](mailto:ahbrown@purdue.edu) or (765) 494-0611.

## Equine Recurrent Uveitis (continued from page 6)



Flymask. (Source: cashelcompany.com)

split up vaccines, giving individual rather than multivalent vaccines and to spread them out over at least two different appointments one week or more apart. Depending on the horse, some veterinarians may also recommend Banamine be given 24 hours prior to vaccination to help decrease ocular inflammation post-vaccination. In the case of high Leptospirosis-risk areas, there is one equine Leptospirosis vaccine created to prevent the systemic dissemination of *L. pomona* which may help reduce the risk of ERU in high risk horses. However, this vaccine is not USDA-licensed for the prevention of ERU and the ability to prevent ERU has not been demonstrated in any trials at this point. Horses with ERU must NOT be given the vaccination as horses with ERU have developed horrible inflammation after receiving the leptospira vaccine.



### References:

1. Gerding, J. C. and Gilger, B. C. (2016), Prognosis and impact of equine recurrent uveitis. *Equine Vet J*, 48: 290-298. doi:10.1111/evj.12451
2. Gilger, B. C. (2017). *Equine Ophthalmology* (3rd ed.). Ames, IA: John Wiley & Sons.
3. Martin, C. L., Pickett, J. P., & Spiess, B. M. (2019). *Ophthalmic Disease in Veterinary Medicine*. Boca Raton, FL: CRC Press, Taylor & Francis Group.
4. McMullen, R. J., & Fischer, B. M. (2017). Medical and surgical management of equine recurrent uveitis. *Veterinary Clinics: Equine Practice*, 33(3), 465-481.
5. Waid, H., Tóth, J., Buijs, L., & Schusser, G. F. (2018). Clinical experiences after the insertion of a Cyclosporine-A drug delivery device in horses with Equine Recurrent Uveitis. *PFERDEHEILKUNDE*, 34(2), 113-120.





Nonprofit Org.  
U.S. Postage  
PAID  
Purdue University

## EQUINE HEALTH UPDATE

is published by:

**Purdue University**

**College of Veterinary Medicine**

**Equine Sports Medicine Center**

1248 Lynn Hall

West Lafayette, Indiana 47907-1248

**ADDRESS SERVICE REQUESTED**

Phone: 765-494-8548

Fax: 765-496-2641

[www.vet.purdue.edu/esmc/](http://www.vet.purdue.edu/esmc/)

With generous support of  
Purdue University's Veterinary  
Teaching Hospital and the College of  
Veterinary Medicine Dean's Office.

Please address all correspondence related  
to this newsletter to the address above.

Editorial Board:

Drs. Couétil L., Hawkins J. and Tinkler S.

Design & layout by:

Elaine Scott Design

EA/EOU



## *The* Equine Sports Medicine Center

Purdue's Equine Sports Medicine Center is dedicated to the education and support of Indiana horsemen and veterinarians through the study of the equine athlete. The Center offers comprehensive evaluations designed to diagnose and treat the causes of poor performance, to provide performance and fitness assessments, and to improve the rehabilitation of athletic horses. Other integral goals of the Center are to pioneer leading-edge research in the area of equine sports medicine, to provide the highest level of training to future equine veterinarians, and to offer quality continuing education to Indiana veterinarians and horsemen. For more information visit our website:

[www.vet.purdue.edu/esmc/](http://www.vet.purdue.edu/esmc/)



Continuum© by Larry Anderson